



PATIENT

Nova Runzer

PRESENTING CLINICAL SIGNS

History: Presented for syncopal episodes. Tachycardia noted on exam. ECG showed VT, treated with lidocaine bolus x 2 2.2mg/kg and on CRI 3mg/kg and sotalol 80mg.

SPECIES

Canine

ECHOCARDIOGRAM FINDINGS

2D, m-mode, color flow and doppler imaging is available. Normal mitral valve leaflets with no prolapse into the left atrial lumen. No mitral regurgitation with a normal left atrial dimension. Normal LV diameter with adequate myocardial function. The tricuspid valve appears normal with no tricuspid regurgitation. Normal right atrial and ventricular diameter and morphology indicating no overt evidence of pulmonary arterial hypertension. The pulmonic and aortic valves are normal in morphology and mobility. Normal pulmonic and aortic outflow velocities with laminar flow. No obvious aortic or pulmonic insufficiency. No pericardial or pleural effusion noted. No obvious cardiac masses.

BREED

Boxer

SEX

Female Spayed

CARDIAC CHART

AGE

9 years

CANINE CARDIAC PARAMETERS	MR VMAX (m/s)	TR VMAX (m/s)	LA/AO (Boon method)	LA/AO (Heart Base; Swe)	FS (%)	EF (%)	EPSS (cm)
NORMAL PARAMETER	4.5-5.5	<2.7	1.3	<1.6	28-40	40-100	<0.6
PATIENT	NA	NA	1.3	1.4	31	60	0.48
CANINE CARDIAC PARAMETERS	HR (BPM)	AV VMAX (m/s)	PV MAX (m/s)	BODY WEIGHT (kg)	LA 2D short axis Base view (cm)	LVIDd Avg; 2D and m-mode short axis (cm)	LVIDs Avg; 2D and m-mode short axis (cm)
NORMAL PARAMETER	50-100	0.7-1.7	0.7-1.6	BELOW	BELOW	BELOW	BELOW
PATIENT	93	1.4	1.4	26.0	2.1	4.1	2.8
*Normal chamber parameters expressed as a mean value (SD)				3	1.27 (5.3)	2.46 (2.46)	1.36 (5.5)
BODY WEIGHT DEPENDENT PARAMETERS				5	1.40 (4.5)	2.74 (5.2)	1.60 (4.7)
<i>*Note: All measurements based upon multi-modal images and methods. An average value is reported.</i>				10	1.50 (3.8)	3.27 (3.5)	2.06 (3.1)
				15	1.83 (2.0)	3.71 (2.4)	2.43 (2.1)
				20	2.02 (1.9)	4.14 (2.2)	2.80 (2.0)
				25	2.18 (2.4)	4.48 (2.9)	3.10 (2.5)
				30	2.33 (3.3)	4.83 (3.9)	3.39 (3.4)
				35	2.48 (4.3)	5.17 (5.0)	3.69 (4.5)
				40	2.62 (5.2)	5.48 (6.1)	3.96 (5.4)
				50	2.88 (7.1)	6.07 (8.3)	4.46 (7.4)

WEIGHT

57.3lbs

INTERPRETED BY

Maggie Machen Lamy, DVM, DACVIM (Cardiology)

IMAGING PERFORMED BY

C. Belan, DVM

HOSPITAL NAME

McKnight 24Hour Animal Hospital

REFERRING VET

Dr. Malaguti

INTERPRETATION OF THE FINDINGS & FURTHER RECOMMENDATIONS

The cardiac structure and function are overtly normal in this patient. There is mild right heart is normal in dimension which is subjective. The left heart dimensions are normal, and the systolic function considered adequate for a large breed dog. No significant valvular insufficiencies or structural issues identified.

INVOICE

22970

DATE

3/8/22



PATIENT

Nova Runzer

SPECIES

Canine

BREED

Boxer

SEX

Female Spayed

AGE

9 years

WEIGHT

57.3lbs

INTERPRETED BY

Maggie Machen Lamy,
DVM, DACVIM
(Cardiology)

IMAGING PERFORMED BY

C. Belan, DVM

HOSPITAL NAME

McKnight 24Hour
Animal Hospital

REFERRING VET

Dr. Malaguti

INVOICE

22970

DATE

3/8/22

A history of ventricular arrhythmias in a senior boxer may suggest ARVC as the likely diagnosis. ARVC can occur with or without systolic dysfunction and structural issues; however, this should be monitored going forward for any progressive development. It is always reasonable to rule out other differentials for VPCs (AUS, tick titers, troponin, etc.) however suspicion is low given the signalment of the patient. Unfortunately, there is always an elevated risk for collapse and sudden death in any arrhythmic patient, and even on medications this risk unfortunately still persists. ARVC carries a HIGHLY variable prognosis, with some dogs able to remain asymptomatic for extended periods of time, and others developing exercise intolerance, syncopal episode, and refractory arrhythmias/sudden death imminently.

Further comment on the arrhythmia (adequacy of the medication, etc.) cannot be made without follow up ECG/holter information. It is important to note that a holter monitor is the gold standard approach to screening patients with ventricular arrhythmias and should be considered prior to anesthesia.

Fish oil supplementation is recommended for dogs with arrhythmias (1000mg of omega 3 and 6 once to twice daily as tolerated).

Monitor at home for collapse, exercise intolerance, and/or lethargy. Anesthesia is not recommended until good arrhythmic control is achieved. Lifelong mild to moderate activity restriction is advised.

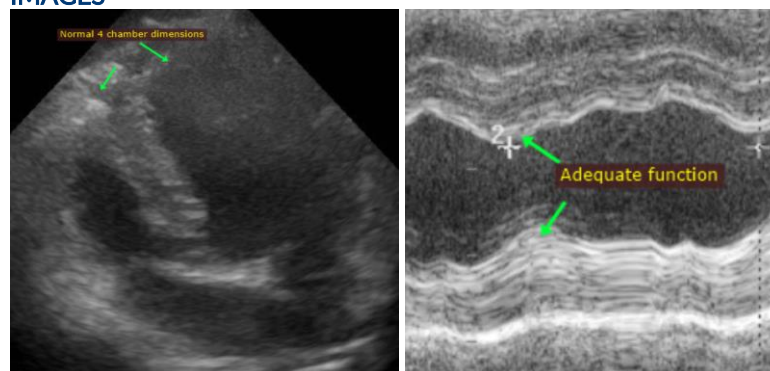
Even with good arrhythmic control, anesthetic risk is remains moderately elevated. Avoid ketamine, telazol, Dexdomitor (or other alpha-2 agonists) and acepromazine. Recommend having lidocaine CRI available for use in the event of worsening ventricular arrhythmias under anesthesia (CRI 50–75mcg/kg/min).

PLAN

Continue Sotalol as prescribed pending follow up ECG/holter evaluation. Consider a holter monitor every 6-12 months as discussed.

Recheck ECG is recommended every 6 months with a recheck echocardiogram annually, sooner if any development of associated clinical signs.

IMAGES





PATIENT

Nova Runzer

The information and recommendations provided are based on the images presented by the referring veterinarian. No evaluation can be communicated regarding pathology that was not visible in the image/video clips provided.

SPECIES

Canine

Thank you for this referral. This report was generated using transcription software, and minor dictation errors may be present. If the clinical or image interpretation does not parallel your findings or if I can be of any further assistance, please contact me.

BREED

Boxer

Maggie Machen Lamy, DVM
Diplomate of the American College of Veterinary Internal Medicine (Cardiology)
info@sonopath.com

SEX

Female Spayed

AGE

9 years

WEIGHT

57.3lbs

INTERPRETED BY

Maggie Machen Lamy,
DVM, DACVIM
(Cardiology)

**IMAGING
PERFORMED BY**

C. Belan, DVM

HOSPITAL NAME

McKnight 24Hour
Animal Hospital

REFERRING VET

Dr. Malaguti

INVOICE

22970

DATE

3/8/22